

## MEDICAL POLICY – 7.01.519

# Treatment of Varicose Veins/Venous Insufficiency

BCBSA Ref. Policy: 7.01.124

Effective Date: Nov. 1, 2024

Last Revised: Oct. 21, 2024

Replaces: 7.01.55, 7.01.76,  
7.01.124, and  
7.01.515

RELATED MEDICAL POLICIES:

10.01.514 Cosmetic and Reconstructive Services

Select a hyperlink below to be directed to that section.

[POLICY CRITERIA](#) | [DOCUMENTATION REQUIREMENTS](#) | [CODING](#)  
[RELATED INFORMATION](#) | [EVIDENCE REVIEW](#) | [REFERENCES](#) | [HISTORY](#)



Clicking this icon returns you to the hyperlinks menu above.

---

## Introduction

Varicose veins are swollen, twisted veins that are visible just below the skin. They most often occur in the legs but can develop in other parts of the body. Veins have valves that keep the blood moving toward the heart. If the valves are weak or damaged, blood can pool in the veins. It's this pooling that causes the veins to swell and appear twisted. Most varicose veins do not result in physical symptoms. On occasion, they can cause symptoms such as pain, an achy feeling, bleeding, or skin ulcers (sores). Varicose veins usually can be treated without surgery by activities such as exercising, raising the legs, or wearing compression stockings. This policy describes when varicose vein surgery or other procedures may be considered medically necessary.

**Note:** The Introduction section is for your general knowledge and is not to be taken as policy coverage criteria. The rest of the policy uses specific words and concepts familiar to medical professionals. It is intended for providers. A provider can be a person, such as a doctor, nurse, psychologist, or dentist. A provider also can be a place where medical care is given, like a hospital, clinic, or lab. This policy informs them about when a service may be covered.

## Policy Coverage Criteria

Procedures	Medical Necessity
<b>Vein ablation procedures:</b> <ul style="list-style-type: none"> <li>• Endovenous thermal ablation (radiofrequency or laser) [36475, 36476, 36478, 36479]</li> <li>• Chemical ablation (microfoam sclerotherapy Varithena) [36465, 36466]</li> <li>• Cyanoacrylate adhesive (VenaSeal Closure System) [36482, 36483]</li> </ul>	<p><b>Endovenous thermal ablation (radiofrequency or laser), chemical ablation (microfoam sclerotherapy, i.e., Varithena [polidocanol 1%]), or cyanoacrylate adhesive (i.e., VenaSeal) may be considered medically necessary for treatment of symptomatic varicose veins (great, small, or accessory saphenous veins)/venous insufficiency when the following criteria have been met:</b></p> <ul style="list-style-type: none"> <li>• There is moderate to severe (greater than 0.5 second) saphenous reflux documented on venous studies</li> </ul> <p><b>AND</b></p> <ul style="list-style-type: none"> <li>• There is documentation of <b>ONE</b> or more of the following four indications: <ul style="list-style-type: none"> <li>○ Ulceration secondary to venous stasis, <b>or</b></li> <li>○ Recurrent superficial thrombophlebitis, <b>or</b></li> <li>○ Hemorrhage or recurrent bleeding episodes from a ruptured superficial varicosity, <b>or</b></li> <li>○ Persistent pain, swelling, itching, burning, or other symptoms are associated with saphenous reflux along with <b>both</b> of the following: <ul style="list-style-type: none"> <li>▪ These symptoms significantly interfere with activities of daily living, <b>and</b></li> <li>▪ Conservative management, including compression therapy (see <a href="#">Definition of Terms</a>) for at least 3 months, has not improved the symptoms</li> </ul> </li> </ul> </li> </ul> <p><b>Treatment that does not meet the criteria described above is considered not medically necessary.</b></p> <p><b>Endovenous radiofrequency or laser ablation procedures of tributary veins is considered investigational.</b></p>

Procedures	Medical Necessity
	<p><b>Endovenous chemical ablation with microfoam sclerotherapy, (i.e., Varithena [polidocanol 1%]) of tributary veins is considered investigational. (36465, 36466)</b></p>
<p><b>Sclerotherapy (36470, 36471)</b></p>	<p><b>Sclerotherapy (e.g., Sotradecol [sodium tetradecyl sulfate], Asclera [polidocanol injection], physician-compounded foam) is considered medically necessary for the treatment of symptomatic varicose tributaries when performed at the same time or within 4-6 weeks of initial treatment (surgical, radiofrequency, or laser) of the saphenous veins.</b></p> <p><b>Note:</b> Sclerotherapy for these indications is limited to a maximum of 3 sclerotherapy treatment sessions per leg.</p> <p><b>Sclerotherapy (e.g., Sotradecol [sodium tetradecyl sulfate], Asclera [polidocanol injection], physician-compounded foam) is considered medically necessary for the treatment of symptomatic varicose tributaries performed after prior treatment (surgical, radiofrequency, or laser) of the saphenous veins, when the following criteria is met:</b></p> <ul style="list-style-type: none"> <li>• Conservative management, including compression therapy (see <a href="#">Definition of Terms</a>) for at least 3 months, has not improved the symptoms</li> </ul> <p><b>Sclerotherapy treatment that does not meet the criteria described above is considered not medically necessary.</b></p> <p><b>Sclerotherapy techniques, (e.g., Sotradecol [sodium tetradecyl sulfate], Asclera [polidocanol injection], physician-compounded foam) of great, small, or accessory saphenous veins are considered investigational. (36470, 36471)</b></p> <p><b>Sclerotherapy of isolated tributary veins without prior or concurrent treatment of saphenous veins is considered investigational.</b></p> <p><b>Sclerotherapy of perforator veins is considered investigational.</b></p>



Procedures	Medical Necessity
<b>Telangiectasia (36468)</b>	<b>Treatment, by any method, of small telangiectasia such as spider veins (1mm or less), superficial reticular veins (1-2 mm), angiomas, and hemangiomas is considered cosmetic.</b>

Treatment	Investigational
<b>Other techniques (0524T, 36473, 36474, 37799)</b>	<p><b>The following techniques are considered investigational for the treatment of any vein(s):</b></p> <ul style="list-style-type: none"> <li>• Endovenous cryoablation</li> <li>• Mechanochemical ablation (e.g., MOCA, ClariVein Catheter)</li> </ul> <p><b>Note:</b> This list may not be all inclusive.</p>

Documentation Requirements
<p><b>Review of this procedure requires the provider to specifically indicate the following in the clinical notes submitted with the request:</b></p> <ul style="list-style-type: none"> <li>• Specific procedures to be performed, including the CPT code(s)</li> </ul> <p><b>AND</b></p> <ul style="list-style-type: none"> <li>• Specific vein to be treated for each CPT code and whether the proposed treatment is to the left leg, right leg, or both legs</li> </ul> <p><b>Additionally, written documentation in the medical record must include:</b></p> <ol style="list-style-type: none"> <li>1. CPT codes for the procedures being requested, and the name of the vein to be treated with each CPT code</li> <li>2. Copy of the venous studies (ultrasound studies evaluating blood flow in the veins)</li> <li>3. One or more indications: <ul style="list-style-type: none"> <li>○ Ulceration secondary to venous stasis (leg ulcers caused by poor blood flow in the veins)</li> <li>○ Recurrent superficial thrombophlebitis (recurrent blood clots or inflammation in a small vein near the surface of the skin)</li> <li>○ Hemorrhage or recurrent bleeding episodes from a ruptured superficial varicosity (bleeding from a varicose vein)</li> <li>○ Persistent pain, swelling, itching, burning, or other symptoms are associated with saphenous reflux (pooling of the blood caused by valves that do not work correctly)</li> </ul> </li> </ol> <p><b>AND</b></p> <ul style="list-style-type: none"> <li>▪ These symptoms significantly interfere with activities of daily living; <b>and</b></li> </ul>

## Documentation Requirements

- Conservative management including compression therapy for at least 3 months has not improved the symptoms

## Coding

Code	Description
<b>CPT</b>	
0524T	Endovenous catheter directed chemical ablation with balloon isolation of incompetent extremity vein, open or percutaneous, including all vascular access, catheter manipulation, diagnostic imaging, imaging guidance and monitoring
36465	Injection of non-compounded foam sclerosant with ultrasound compression maneuvers to guide dispersion of the injectate, inclusive of all imaging guidance and monitoring; single incompetent extremity truncal vein (e.g., great saphenous vein, accessory saphenous vein) (Varithena/polidocanol 1%)
36466	Injection of non-compounded foam sclerosant with ultrasound compression maneuvers to guide dispersion of the injectate, inclusive of all imaging guidance and monitoring; multiple incompetent truncal veins (e.g., great saphenous vein, accessory saphenous vein), same leg (Varithena/polidocanol 1%)
36468	Single or multiple injections of sclerosing solutions, spider veins (telangiectasia); limb or trunk
36470	Injection of sclerosing solution; single vein
36471	Injection of sclerosing solution; multiple veins, same leg
36473	Endovenous ablation therapy of incompetent vein, extremity, inclusive of all imaging guidance and monitoring, percutaneous, mechanochemical; first vein treated (e.g., MOCA ClariVein)
36474	Endovenous ablation therapy of incompetent vein, extremity, inclusive of all imaging guidance and monitoring, percutaneous, mechanochemical; subsequent vein(s) treated in a single extremity, each through separate access sites (List separately in addition to code for primary procedure) (e.g., MOCA ClariVein)
36475	Endovenous ablation therapy of incompetent vein, extremity, inclusive of all imaging guidance and monitoring, percutaneous, radiofrequency; first vein treated
36476	Endovenous ablation therapy of incompetent vein, extremity, inclusive of all imaging guidance and monitoring, percutaneous, radiofrequency; second and subsequent veins treated in a single extremity, each through separate access sites (List separately in addition to code for primary procedure)

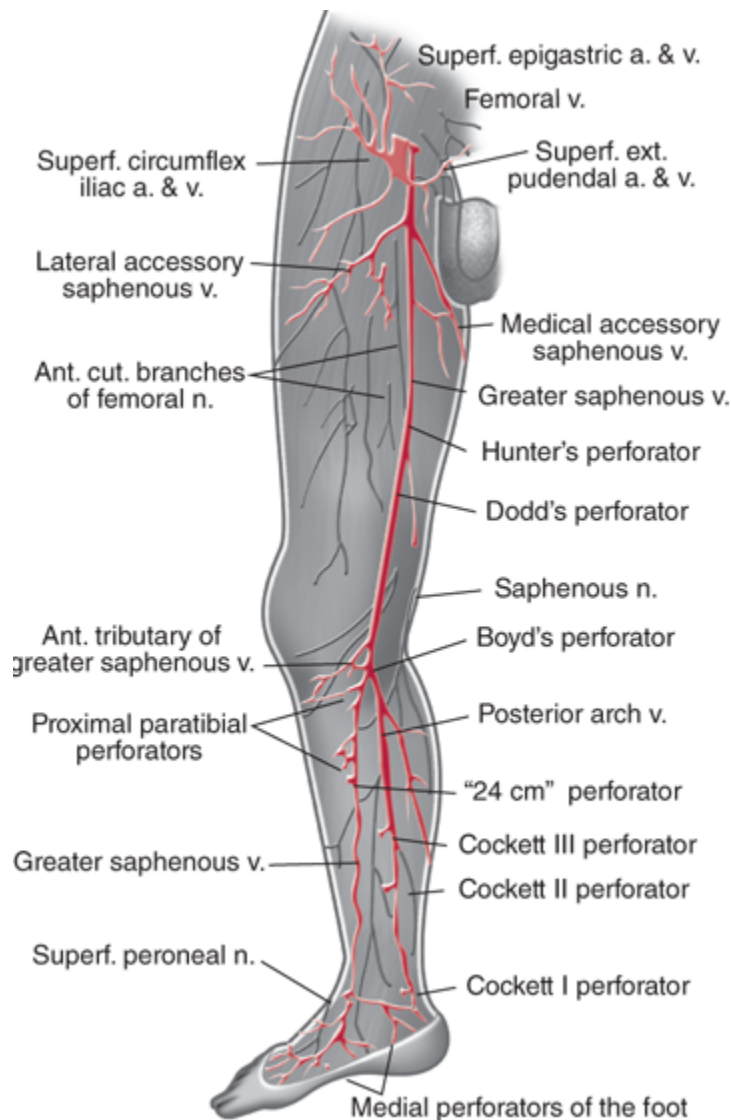
Code	Description
36478	Endovenous ablation therapy of incompetent vein, extremity, inclusive of all imaging guidance and monitoring, percutaneous, laser; first vein treated
36479	Endovenous ablation therapy of incompetent vein, extremity, inclusive of all imaging guidance and monitoring, percutaneous, laser; second and subsequent veins treated in a single extremity, each through separate access sites (List separately in addition to code for primary procedure)
36482	Endovenous ablation therapy of incompetent vein, extremity, by transcatheter delivery of a chemical adhesive (e.g., cyanoacrylate) remote from the access site, inclusive of all imaging guidance and monitoring, percutaneous; first vein treated (VenaSeal)
36483	Endovenous ablation therapy of incompetent vein, extremity, by transcatheter delivery of a chemical adhesive (e.g., cyanoacrylate) remote from the access site, inclusive of all imaging guidance and monitoring, percutaneous; subsequent vein(s) treated in a single extremity, each through separate access sites (List separately in addition to code for primary procedure) (VenaSeal)
37799	Unlisted procedure, vascular surgery

**Note:** CPT codes, descriptions and materials are copyrighted by the American Medical Association (AMA). HCPCS codes, descriptions and materials are copyrighted by Centers for Medicare Services (CMS).

## Related Information



## Veins of the lower extremity



Source: Gerard M. Doherty: Current Diagnosis & Treatment: Surgery, 14th Edition.

## Definition of Terms

**Accessory saphenous veins:** Veins that travel in parallel with the greater and lesser saphenous veins and are generally 2 to 2.5 mm in their normal state.

**Clinical-Etiologic-Anatomic-Pathophysiology (CEAP) classification system:** The standard classification of venous disease considers the clinical, etiologic, anatomic, and pathologic (CEAP) characteristics of venous insufficiency. See [Table 1](#) below.

**Table 1. Clinical Portion of the CEAP Classification System**

Class	Clinical Classification
C0	No visible or palpable signs of venous disease
C1	Telangiectasies or reticular veins
C2	Varicose veins
C2r	Recurrent varicose veins
C3	Edema
C4	Changes in skin and subcutaneous tissue secondary to chronic venous disease (CVD)
C4a	Pigmentation and eczema
C4b	Lipodermatosclerosis and atrophie blanche
C4c	Corona phlebectatica
C5	Healed venous ulcer
C6	Active venous ulcer
C6r	Recurrent active venous ulcer
S	Symptomatic including ache, pain, tightness, skin irritation, heaviness, muscle cramps, and other complaints attributable to venous dysfunction
A	Asymptomatic

Adapted from: [https://www.jvsvenous.org/article/S2213-333X\(20\)30063-9/pdf](https://www.jvsvenous.org/article/S2213-333X(20)30063-9/pdf). Accessed June 5, 2024. CEAP: Clinical, Etiologic, Anatomic, Pathophysiologic classification system; CVD, chronic venous disease. Each clinical class subcharacterized by a subscript indicates the presence (symptomatic, s) or absence (asymptomatic, a) of symptoms attributable to venous disease.

**Compression Therapy:** Compression hosiery or stockings are often the first line of treatment for varicose veins. Compression stockings are generally thought to be effective in a range of 20 mmHg to 40mmHg. The Society for Vascular Surgery/American Venous Forum recommends compression therapy of 20-30 mmHg for individuals with symptomatic varicose veins. Compression stockings of 20-30mmHg are available over the counter without a prescription.

**Greater/long saphenous vein:** Superficial vein running the entire length of the leg and is generally 3 mm in its normal state. A typical GSV contains an average of 7 valves throughout its entire length, and it is the most common superficial vein to develop venous reflux.

**Lesser (small)/short saphenous veins:** Superficial vein of the calf and is generally 2.5 mm in its normal state. The small saphenous vein originates at the back of the ankle near the outer



malleolus bone, and usually runs up the back of the lower leg to the popliteal vein behind the knee.

**Moderate to severe reflux:** In current practice, most vascular laboratories consider the presence of venous flow reversal for greater than 0.5 second with proximal compression, Valsalva maneuver, or distal compression and release to represent pathologic reflux.

**Neovascularization** is the proliferation of new blood vessels in tissue and occurs more frequently following vein stripping.

**Perforator veins:** These connect superficial veins to deep veins. They contain one-way valves to direct the blood from the superficial system to the deep system and are generally less than 3mm in their normal state.

**Recanalization** is the restoration of the lumen of a vein after it has been occluded; this occurs more frequently following treatment with endovenous techniques.

**Stab avulsion:** This technique is also known as stab/hook phlebectomy. Stab avulsion results in removal of the varicose veins through incisions that are 2-3 mm in length. The veins are hooked with a tiny hook-like instrument and pulled out. The wounds are closed with tapes, not sutures, and the leg is wrapped in elastic compression support. Once healed, the incision sites are almost invisible.

**Telangiectasia/spider veins:** Very small ( $\leq 1$  mm in diameter) thread veins found commonly just under the surface of the skin, usually not distorting skin or surrounding tissues. These are not considered varicose veins.

**Tributary veins:** Veins that empty into a larger vein.

## Varicose Vein Recurrence

Varicose vein recurrence may be associated with technical reasons such as an inexperienced surgeon performing an inadequate complete primary procedure or tactical reasons such as a poor choice of procedures for managing the present venous disease. Types of recurrence commonly seen are "residual varices which are veins that are present but have not been treated in a procedure performed as late as one month earlier, recurrent varices which are recanalized veins that have occurred and are refluxing one month after a previously performed procedure, or new refluxing veins that have developed in an anatomic region where there were previously no vessels", also known as neovascularization.<sup>68,69</sup>

## Benefit Application

Treatment of some varicose veins may be considered cosmetic if not associated with significant clinical symptoms and documented reflux at the saphenofemoral or saphenopopliteal junction, and thus contract exclusions for cosmetic therapies may apply to coverage eligibility. Note that the term "varicose veins" does not apply to the telangiectatic dermal veins, which may be described as "spider veins" or "broken blood vessels." While abnormal in appearance, these veins typically are not associated with any other symptoms (e.g., pain or heaviness), and their treatment is considered cosmetic.

## Evidence Review

---

### Description

A variety of treatment modalities are available to treat varicose veins/venous insufficiency, including surgery, thermal ablation, sclerotherapy, mechanochemical ablation (MOCA), cyanoacrylate adhesive (CAC), and cryotherapy. The application of each modality is influenced by the severity of the symptoms, type of vein, source of venous reflux, and the use of other (prior or concurrent) treatments.

### Background

#### Venous Reflux/Venous Insufficiency

The venous system of the lower extremities consists of the superficial veins (this includes the great and small saphenous and accessory, or duplicate, veins that travel in parallel with the great and small saphenous veins), the deep system (popliteal and femoral veins), and perforator veins that cross through the fascia and connect the deep and superficial systems. One-way valves are present within all veins to direct the return of blood up the lower limb. Because the venous pressure in the deep system is generally greater than that of the superficial system, valve incompetence at any level may lead to backflow (venous reflux) with pooling of blood in superficial veins. Varicose veins with visible varicosities may be the only sign of venous reflux, although itching, heaviness, tension, and pain may also occur. Chronic venous insufficiency

secondary to venous reflux can lead to thrombophlebitis, leg ulcerations, and hemorrhage. The CEAP classification of venous disease considers the clinical, etiologic, anatomic, and pathologic characteristics of venous insufficiency, ranging from class 0 (no visible sign of disease) to class 6 (active ulceration).

## **Treatment**

Treatment of venous reflux/venous insufficiency seeks to reduce abnormal pressure transmission from the deep to the superficial veins. Conservative medical treatment consists of elevation of the extremities, graded compression, and wound care when indicated. Conventional surgical treatment consists of identifying and correcting the site of reflux by ligation of the incompetent junction followed by stripping of the vein to redirect venous flow through veins with intact valves. While most venous reflux is secondary to incompetent valves at the saphenofemoral or saphenopopliteal junctions, reflux may also occur at incompetent valves in the perforator veins or the deep venous system. The competence of any single valve is not static and may be pressure dependent. For example, accessory saphenous veins may have independent saphenofemoral or saphenopopliteal junctions that become incompetent when the great or small saphenous veins are eliminated, and blood flow is diverted through the accessory veins.

## **Treatment of Saphenous Veins and Tributaries**

Saphenous veins include the great and small saphenous and accessory saphenous veins that travel in parallel with the great or small saphenous veins. Tributaries are veins that empty into a larger vein. Treatment of venous reflux has traditionally included the following:

- Identification by preoperative Doppler ultrasonography of the valvular incompetence
- Control of the most proximal point of reflux, traditionally by suture ligation of the incompetent saphenofemoral or saphenopopliteal junction
- Removal of the superficial vein from circulation, e.g., by stripping of the great and/or small saphenous veins
- Removal of varicose tributaries (at the time of the initial treatment or subsequently) by stab avulsion (phlebectomy) or injection sclerotherapy.



Minimally invasive alternatives to ligation and stripping have been investigated. These include forms of sclerotherapy, CAC, and thermal ablation using cryotherapy, high frequency radio waves (200–300 kHz), or laser energy.

## Thermal Ablation

Radiofrequency ablation (RFA) is performed using a specially designed catheter inserted through a small incision in the distal medial thigh to within 1 to 2 cm of the saphenofemoral junction. The catheter is slowly withdrawn, closing the vein. Laser ablation is performed similarly. A laser fiber is introduced into the great saphenous vein under ultrasound guidance. The laser is then activated and slowly removed, along the course of the saphenous vein. Cryoablation uses extreme cold. The objective of endovenous techniques is to injure the vessel, causing retraction and subsequent fibrotic occlusion of the vein. Technical developments since thermal ablation procedures were initially introduced include the use of perivenous tumescent anesthesia, which allows successful treatment of veins larger than 12 mm in diameter and helps to protect adjacent tissue from thermal damage during treatment of the small saphenous vein.

## Sclerotherapy

The objective of sclerotherapy is to destroy the endothelium of the target vessel by injecting an irritant solution (either a detergent, osmotic solution, or chemical irritant), ultimately occluding the vessel. Treatment success depends on accurate injection of the vessel, an adequate injectate volume and concentration of sclerosant, and compression. Historically, larger veins and very tortuous veins were not considered good candidates for sclerotherapy due to technical limitations. Technical improvements in sclerotherapy have included the routine use of Duplex ultrasound to target refluxing vessels, luminal compression of the vein with anesthetics, and a foam/sclerosant injectate in place of liquid sclerosant. Foam sclerosants are produced by forcibly mixing a gas (e.g., air or carbon dioxide) with a liquid sclerosant (e.g., polidocanol or sodium tetradecyl sulfate). Physician-compounded foam is produced at the time of treatment. A commercially available microfoam sclerosant with a proprietary gas mix is available that is proposed to provide smaller and more consistent bubble size than what is produced with physician-compounded sclerosant foam.

## Endovenous Mechanochemical Ablation (MOCA)

Endovenous mechanochemical ablation uses both sclerotherapy and mechanical damage to the lumen. Following ultrasound imaging, a disposable catheter with a motor drive is inserted into the distal end of the target vein and advanced to the saphenofemoral junction. As the catheter is pulled back, a wire rotates at 3500 rpm within the lumen of the vein, abrading the lumen. At the same time, a liquid sclerosant (sodium tetradecyl sulfate) is infused near the rotating wire. It is proposed that mechanical ablation allows for better efficacy of the sclerosant, and results in less pain and risk of nerve injury without the need for the tumescent anesthesia used with endovenous thermal ablation techniques (RFA, endovenous laser ablation).

## Cyanoacrylate Adhesive

A cyanoacrylate adhesive is a clear, free-flowing liquid that polymerizes in the vessel via an anionic mechanism (i.e., polymerizes into a solid material on contact with body fluids or tissue). The adhesive is gradually injected along the length of the vein in conjunction with ultrasound and manual compression. The acute coaptation halts blood flow through the vein until the implanted adhesive becomes fibrotically encapsulated and establishes chronic occlusion of the treated vein. Cyanoacrylate glue has been used as a surgical adhesive and sealant for a variety of indications, including gastrointestinal bleeding, embolization of brain arteriovenous malformations, and to seal surgical incisions or other skin wounds.

## Transilluminated Powered Phlebectomy (TIPP)

Transilluminated powered phlebectomy (TIPP) is an alternative to stab avulsion or hook phlebectomy. This procedure uses two instruments: an illuminator, which also provides irrigation, and a resector, which has an oscillating tip and suction pump. Following removal of the saphenous vein, the illuminator is introduced via a small incision in the skin and tumescence solution (anesthetic and epinephrine) is infiltrated along the course of the varicosity. The resector is then inserted under the skin from the opposite direction, and the oscillating tip is placed directly beneath the illuminated veins to fragment and loosen the veins from the supporting tissue. Irrigation from the illuminator is used to clear the vein fragments and blood through aspiration and additional drainage holes. The illuminator and resector tips may then be repositioned, thereby reducing the number of incisions needed when compared with stab avulsion or hook phlebectomy. It has been proposed that TIPP might decrease surgical time,



decrease complications such as bruising, and lead to a faster recovery than established procedures.

## Summary of Evidence

### Saphenous Veins

For individuals who have varicose veins/venous insufficiency and saphenous vein reflux who receive endovenous thermal ablation (radiofrequency or laser), the evidence includes randomized controlled trials (RCTs) and systematic reviews of controlled trials. The relevant outcomes are symptoms, change in disease status, morbid events, quality of life (QOL), and treatment-related morbidity. There are a number of large RCTs and systematic reviews of RCTs assessing endovenous thermal ablation of the saphenous veins. Comparison with the standard of ligation and stripping at 2- to 5-year follow-up has supported the use of both endovenous laser ablation and radiofrequency ablation (RFA). Evidence has suggested that ligation and stripping lead to more neovascularization, while thermal ablation leads to more recanalization, resulting in similar clinical outcomes for endovenous thermal ablation and surgery. The evidence is sufficient to determine that the technology results in an improvement in the net health outcome.

For individuals who have varicose veins/venous insufficiency and saphenous vein reflux who receive microfoam sclerotherapy, the evidence includes RCTs and systematic reviews. The relevant outcomes are symptoms, change in disease status, morbid events, quality of life, and treatment-related morbidity. In a Cochrane review, ultrasound-guided foam sclerotherapy was inferior to both ligation and stripping and endovenous laser ablation for technical success up to 5 years and beyond 5 years, but there was no significant difference between treatments for recurrence up to 3 years and at 5 years. For physician-compounded sclerotherapy, there is high variability in success rates and some reports of serious adverse events. By comparison, rates of occlusion with the microfoam sclerotherapy (polidocanol 1%) approved by the US Food and Drug Administration (FDA) are similar to those reported for endovenous laser ablation or stripping. Results of a noninferiority trial of physician-compounded sclerotherapy have indicated that once occluded, recurrence rates at two years are similar to those of ligation and stripping. Together, this evidence indicates that the more consistent occlusion with the microfoam sclerotherapy preparation will lead to recurrence rates similar to ligation and stripping in the longer term. The evidence is sufficient to determine that the technology results in an improvement in the net health outcome.



For individuals who have varicose veins/venous insufficiency and saphenous vein reflux who receive mechanochemical ablation (MOCA), the evidence includes four RCTs with six months to two-year results that compared MOCA to thermal ablation, and a prospective cohort with follow-up out to five years. The relevant outcomes are symptoms, change in disease status, morbid events, quality of life, and treatment-related morbidity. MOCA is a combination of liquid sclerotherapy with mechanical abrasion. A potential advantage of this procedure compared with thermal ablation is that MOCA does not require tumescent anesthesia and may result in less pain during the procedure. Results to date have been mixed regarding a reduction in intraprocedural pain compared to thermal ablation procedures. Occlusion rates at six months to two years from RCTs indicate lower anatomic success rates compared to thermal ablation, but a difference in clinical outcomes at these early time points has not been observed. Experience with other endoluminal ablation procedures suggests that lower anatomic success in the short term is associated with recanalization and clinical recurrence between two to five years. The possibility of later clinical recurrence is supported by a prospective cohort study with five-year follow-up following treatment with MOCA. However, there have been improvements in technique since the cohort study was begun, and clinical progression is frequently observed with venous disease. Because of these limitations, longer follow-up of the more recently conducted RCTs is needed to establish the efficacy and durability of this procedure compared with the criterion standard of thermal ablation. The evidence is insufficient to determine that the technology results in an improvement in the net health outcome.

For individuals who have varicose veins/venous insufficiency and saphenous vein reflux who receive cyanoacrylate adhesive (CAC), the evidence includes three RCTs and a prospective cohort study. The relevant outcomes are symptoms, change in disease status, morbid events, quality of life, and treatment-related morbidity. Evidence includes a multicenter noninferiority trial with follow-up through 36 months, 2 RCTs with follow-up through 24 months, and a prospective cohort with 30-month follow-up. The short-term efficacy of VenaSeal CAC has been shown to be noninferior to RFA at up to 36 months. At 24 and 36 months the study had greater than 20% loss to follow-up, but loss to follow-up was similar in the 2 groups at the long-term follow-up and is not expected to influence the comparative results. Another RCT (N=248) comparing VenaSeal CAC with RFA found similar proportions of vein closures at 24 months with both treatments, with potentially shorter procedure duration with CAC versus RFA. A third RCT (N=525) with an active CAC ingredient (N-butyl cyanoacrylate) that is currently available outside of the US found no significant differences in vein closure between CAC and thermal ablation controls at 24-month follow-up. The CAC procedure and return to work were shorter and pain scores were lower compared to thermal ablation, although the subjective pain scores may have been influenced by differing expectations in this study. A prospective cohort study reported high closure rates at 30 months. Overall, results indicate that outcomes from CAC are at least as



good as thermal ablation techniques, the current standard of care. The evidence is sufficient to determine that the technology results in an improvement in the net health outcome.

For individuals who have varicose veins/venous insufficiency and saphenous vein reflux who receive cryoablation, the evidence includes RCTs. The relevant outcomes are symptoms, change in disease status, morbid events, quality of life, and treatment-related morbidity. Results from a recent RCT of cryoablation have indicated that this therapy is inferior to conventional stripping. Studies showing a benefit on health outcomes are needed. The evidence is insufficient to determine that the technology results in an improvement in the net health outcome.

## **Varicose Tributary Veins**

For individuals who have varicose tributary veins who receive ablation (stab avulsion, sclerotherapy, or phlebectomy) of tributary veins, the evidence includes RCTs and systematic reviews of RCTs. The relevant outcomes are symptoms, change in disease status, morbid events, quality of life, and treatment-related morbidity. The literature has shown that sclerotherapy is effective for treating tributary veins following occlusion of the saphenofemoral or saphenopopliteal junction and saphenous veins. No studies have been identified comparing RFA or laser ablation of tributary veins with standard procedures (microphlebectomy and/or sclerotherapy). Transilluminated powered phlebectomy (TIPP) is effective at removing varicosities; outcomes are comparable to available alternatives such as stab avulsion and hook phlebectomy. The evidence is sufficient to determine that the technology results in an improvement in the net health outcome.

## **Perforator Veins**

For individuals who have perforator vein reflux who receive ablation (e.g., subfascial endoscopic perforator surgery) of perforator veins, the evidence includes RCTs and systematic reviews of RCTs, and a retrospective study. The relevant outcomes are symptoms, change in disease status, morbid events, quality of life, and treatment-related morbidity. The literature has indicated that the routine ligation or ablation of incompetent perforator veins is not necessary for the treatment of varicose veins/venous insufficiency at the time of superficial vein procedures. However, when combined superficial vein procedures and compression therapy have failed to improve symptoms (i.e., ulcers), treatment of perforator vein reflux may be as beneficial as an alternative (e.g., deep vein valve replacement). Comparative studies are needed to determine the most effective method of ligating or ablating incompetent perforator veins. Subfascial





endoscopic perforator surgery is possibly as effective as the Linton procedure with a reduction in adverse events. Endovenous ablation with specialized laser or radiofrequency probes has been shown to effectively ablate incompetent perforator veins with a potential decrease in morbidity compared with surgical interventions. The evidence is sufficient to determine that the technology results in an improvement in the net health outcome.

## Ongoing and Unpublished Clinical Trials

Some currently ongoing and unpublished trials that might influence this policy are listed in [Table 2](#).

**Table 2. Summary of Key Trials**

NCT No.	Trial Name	Planned Enrollment	Completion Date
<b>Ongoing</b>			
<a href="#">NCT05633277</a>	Outcomes of Sclerotherapy of the Ulcer Bed Compared to a Combination of Ablation and Injections	30	Mar 2024
<a href="#">NCT04737941</a>	Finnish Venous Ulcer Study	248	Mar 2026
<a href="#">NCT03820947<sup>a</sup></a>	Global, Post-Market, Prospective, Multi-Center, Randomized Controlled Trial of the VenaSeal Closure System vs. Surgical Stripping or Endothermal Ablation (ETA) for the Treatment of Early & Advanced Stage Superficial Venous Disease	500	Apr 2028
<b>Unpublished</b>			
<a href="#">NCT03392753</a>	Randomised Controlled Trial of Mechanochemical Ablation Versus Cyanoacrylate Adhesive for the Treatment of Varicose Veins	167	Dec 2021
<a href="#">NTR4613<sup>a</sup></a>	Mechanochemical endovenous ablation versus radiofrequency ablation in the treatment of primary small saphenous vein insufficiency (MESSI trial)	160	Apr 2020

NCT: national clinical trial. NTR: Netherlands Trial Registry.

<sup>a</sup> Denotes industry-sponsored or cosponsored trial

## Clinical Input from Physician Specialty Societies and Academic Medical Centers

While the various physician specialty societies and academic medical centers may collaborate with and make recommendations during this process, through the provision of appropriate reviewers, input received does not represent an endorsement or position statement by the physician specialty societies or academic medical centers, unless otherwise noted.

In response to requests, input was received from four physician specialty societies while this policy was under review in 2015. There was no agreement on the need to treat varicose tributaries to improve functional outcomes in the absence of saphenous vein disease. Input was also mixed on the use of MOCA and CAC.

## Practice Guidelines and Position Statements

The purpose of the following information is to provide reference material. Inclusion does not imply endorsement or alignment with the policy conclusions.

Guidelines or position statements will be considered for inclusion if they were issued by, or jointly by, a US professional society, an international society with US representation, or National Institute for Health and Care Excellence (NICE). Priority will be given to guidelines that are informed by a systematic review, include strength of evidence ratings, and include a description of management of conflict of interest.

## American Venous Forum et al

In 2020, in response to published reports of potentially inappropriate application of venous procedures, the American Venous Forum, Society for Vascular Surgery, American Vein and Lymphatic Society, and the Society of Interventional Radiology published appropriate use criteria for the treatment of chronic lower extremity venous disease.<sup>62</sup> Appropriate use criteria were developed using the RAND/UCLA method incorporating best available evidence and expert opinion.

Appropriate use criteria were determined for various scenarios (e.g., symptomatic, asymptomatic, CEAP [Clinical, Etiology, Anatomy and Pathophysiology] class, axial reflux, saphenofemoral junction reflux) for the following:



- Saphenous vein ablation
  - Great saphenous vein
  - Small saphenous vein
  - Accessory great saphenous vein
- Nontruncal varicose veins
- Diseased tributaries associated with saphenous ablation
- Perforator Veins
- Iliac Vein or inferior vena cava stenting as a first line treatment
- Duplex ultrasound
- Timing and Reimbursement.

Treatment of saphenous veins for asymptomatic CEAP class 1 and 2, or symptomatic class 1, was considered to be rarely appropriate or never appropriate, and treatment of symptomatic CEAP class 2, 3, and 4 to 6 without reflux was rated as never appropriate. Based on the 2011 Guidelines from the Society for Vascular Surgery and American Venous Forum (see below), treatment of perforator veins for asymptomatic or symptomatic CEAP class 1 and 2 was considered to be rarely appropriate or never appropriate. Perforator vein treatment was rated as appropriate for CEAP classes 4 to 6 and may be appropriate for CEAP class 3. Except for a recommendation to use endovenous procedures for perforator vein ablation, techniques used to treat veins in these scenarios were not evaluated.

## **Society for Vascular Surgery, American Vein and Lymphatic Society, and American Venous Forum**

The Society for Vascular Surgery and the American Venous Forum (2011) published joint clinical practice guidelines.<sup>63</sup> **Table 3** provides the recommendations.



**Table 3. Guidelines on Management of Varicose Veins and Associated Chronic Venous Diseases**

<b>Recommendation</b>	<b>Grade<sup>a</sup></b>	<b>SOR</b>	<b>QOE</b>
<b>Compression therapy for venous ulcerations and varicose veins</b>			
Compression therapy is recommended as the primary treatment to aid healing of venous ulceration	1B	Strong	Moderate
To decrease the recurrence of venous ulcers, ablation of the incompetent superficial veins in addition to compression therapy is recommended	1A	Strong	High
Use of compression therapy for individuals with symptomatic varicose veins is recommended	2C	Weak	Low
Compression therapy as the primary treatment if the individual is a candidate for saphenous vein ablation is not recommended	1B	Strong	Moderate
<b>Treatment of the incompetent great saphenous vein</b>			
Endovenous thermal ablation (radiofrequency or laser) is recommended over chemical ablation with foam or high ligation and stripping due to reduced convalescence and less pain and morbidity. Cryostripping is a technique that is new in the United States, and it has not been fully evaluated.	1B	Strong	Moderate
<b>Varicose tributaries</b>			
Phlebectomy or sclerotherapy are recommended to treat varicose tributaries	1B	Strong	Moderate
Transilluminated powered phlebectomy using lower oscillation speeds and extended tumescence is an alternative to traditional phlebectomy	2C	Weak	Low
<b>Perforating vein incompetence</b>			
Selective treatment of perforating vein incompetence in individuals with simple varicose veins is not recommended	1B	Strong	Moderate
Treatment of pathologic perforating veins (outward flow of $\geq 500$ ms duration, with a diameter of $\geq 3.5$ mm) located underneath healed or active ulcers (CEAP class C5-C6) is recommended	2B	Weak	Moderate

CEAP: Clinical Etiology Anatomy Pathophysiology; QOE: quality of evidence; SOR: strength of recommendation.

<sup>a</sup> Grading: strong = 1 or weak = 2, based on a level of evidence that is either high quality = A, moderate quality = B, or low quality = C.

The Society for Vascular Surgery, the American Vein and Lymphatic Society (AVLS), and the American Venous Forum published a joint clinical practice guideline in 2022 on management of lower extremity varicose veins.<sup>64</sup> The guideline will be published in sections; the first part (published in 2022) focuses on duplex scanning and treatment of superficial truncal reflux. Superficial truncal veins are defined as the great saphenous vein, small saphenous vein, anterior

accessory great saphenous vein, and posterior accessory great saphenous vein. A summary of the 2022 guideline recommendations is provided in [Table 4](#). The second part of the guideline was published in 2023 and focuses on the management of varicose vein patients with compression, treatment with drugs and nutritional supplements, evaluation and treatment of varicose tributaries, superficial venous aneurysms, and management of complications of varicose veins and their treatment.<sup>65</sup> Relevant guideline recommendations regarding the management of varicose veins and varicose tributaries are summarized in [Table 5](#).

**Table 4. Summary of Recommended Treatment of Superficial Truncal Reflux**

Recommendation	Grade <sup>a</sup>	SOR	QOE
<b>Symptomatic varicose veins and axial reflux</b>			
Reflux in the great or small saphenous vein - superficial venous intervention preferred over long-term compression stockings	1B	Strong	Moderate
Reflux in the anterior accessory or posterior accessory great saphenous vein - superficial venous intervention preferred over long-term compression stockings	2C	Weak	Low
Reflux in the superficial truncal vein - compression therapy suggested for primary treatment	2C	Weak	Low
Reflux in the great saphenous vein - endovenous ablation preferred over high ligation and stripping <sup>b</sup>	1B	Strong	Moderate
Reflux in the small saphenous vein - endovenous ablation preferred over high ligation and stripping <sup>b</sup>	1C	Strong	Low
Reflux in the anterior accessory or posterior accessory great saphenous vein - endovenous ablation (with phlebectomy if needed) over ligation and stripping <sup>b</sup>	2C	Weak	Low
Individuals who place a high priority on long-term outcomes (quality of life and recurrence) - laser ablation, radiofrequency ablation, or ligation and stripping over ultrasound-guided foam sclerotherapy	2C or 2B	Weak	Moderate or Low
<b>Symptomatic axial reflux</b>			
Reflux in the great saphenous vein - thermal and nonthermal ablation recommended	1B	Strong	Moderate
Reflux in the small saphenous vein - thermal and nonthermal ablation recommended	1C	Strong	Low
Reflux in the anterior accessory or posterior accessory great saphenous vein - either thermal or nonthermal ablation suggested	2C	Weak	Low
<b>Varicose veins (CEAP class C2)</b>			

Recommendation	Grade <sup>a</sup>	SOR	QOE
Reflux in the great or small saphenous vein - recommend against concomitant initial ablation and treatment of incompetent perforating veins	1C	Strong	Low
Reflux in the anterior accessory or posterior accessory great saphenous vein - recommend against concomitant initial ablation and treatment of incompetent perforating veins	2C	Weak	Low
Persistent or recurrent symptoms after previous complete ablation - treatment of perforating vein incompetence suggested	2C	Weak	Low
<b>Symptomatic reflux and associated varicosities</b>			
Reflux in the great or small saphenous vein - ablation and concomitant phlebectomy or ultrasound-guided foam sclerotherapy recommended	1C	Strong	Low
Reflux in the anterior accessory or posterior accessory great saphenous vein - ablation and concomitant phlebectomy or ultrasound-guided foam sclerotherapy suggested	2C	Weak	Low

CEAP: Clinical Etiology Anatomy Pathophysiology; QOE: quality of evidence; SOR: strength of recommendation.

a Grading: strong = 1 or weak = 2, based on a level of evidence that is either high quality = A, moderate quality = B, or low quality = C. b Ligation and stripping can be performed if endovenous ablation is not feasible.

**Table 5. Summary of Recommendations for Varicose Veins and Varicose Tributaries**

Recommendation	Grade <sup>a</sup>	SOR	QOE
<b>Endovenous Ablation vs High Ligation and Stripping</b>			
For individuals with symptomatic varicose veins and axial reflux in the GSV, who are candidates for intervention, we recommend treatment with endovenous ablation over HL&S of the GSV.	1	Strong	Moderate
For individuals with symptomatic varicose veins and axial reflux in the SSV, who are candidates for intervention, we recommend treatment with endovenous ablation over ligation and stripping of the SSV.	1	Strong	Low to very low
For individuals with symptomatic varicose veins and axial reflux in the AAGSV or PAGSV, who are candidates for intervention, we suggest treatment with endovenous ablation, with additional phlebectomy, if needed, over ligation and stripping of the accessory vein.	2	Weak	Low to very low
For individuals with symptomatic varicose veins and axial reflux in the GSV or SSV, we recommend treatment with HL&S of the saphenous vein if technology or expertise in endovenous ablation is not available or if the venous anatomy precludes endovenous treatment.	1	Strong	Moderate

Recommendation	Grade <sup>a</sup>	SOR	QOE
For individuals with symptomatic varicose veins and axial reflux in the AAGSV or PAGSV, we suggest treatment with ligation and stripping of the accessory saphenous vein, with additional phlebectomy if needed, if technology or expertise in endovenous ablations is not available or if the venous anatomy precludes endovenous treatment.	2	Weak	Low to very low
For individuals with symptomatic varicose veins and axial reflux in the GSV who place a high priority on the long-term outcomes of treatment (QOL and recurrence), we suggest treatment with EVLA, RFA, or HL&S over physician-compounded UGFS, because of long-term improvement of QOL and reduced recurrence.	2	Weak	Moderate
For individuals with symptomatic varicose veins and axial reflux in the SSV, we suggest treatment with EVLA, RFA, or ligation and stripping from the knee to the upper or midcalf over physician-compounded UGFS because of long-term improvement of QOL and reduced recurrence.	2	Weak	Low to very low
For individuals with symptomatic varicose veins and axial reflux in the AAGSV or PAGSV who place a high priority on the long-term outcomes of treatment (QOL and recurrence), we suggest treatment of the refluxing superficial trunk with endovenous laser ablation, RFA, or HL&S, with additional phlebectomy if needed, over physician-compounded UGFS because of long-term improvement of QOL and reduced recurrence.	2	Weak	Low to very low
<b>Thermal vs. nonthermal ablation of superficial truncal veins</b>			
For individuals with symptomatic axial reflux of the GSV, we recommend either thermal or nonthermal ablation from the groin to below the knee, depending on the available expertise of the treating physician and the preference of the patient.	1	Strong	Moderate
For individuals with symptomatic axial reflux of the SSV, we recommend either thermal or nonthermal ablation from the knee to the upper or midcalf, depending on the available expertise of the treating physician and the preference of the patient.	1	Strong	Low to very low
For individuals with symptomatic axial reflux of the AAGSV or PAGSV, we suggest either thermal or nonthermal ablation, with additional phlebectomy if needed, depending on the available expertise of the treating physician and the preference of the patient.	2	Weak	Low to very low
<b>Telangiectasias and reticular veins</b>			
For individuals with symptomatic telangiectasias and reticular veins, we recommend sclerotherapy with liquid or foam.	1	Strong	Moderate
For individuals with symptomatic telangiectasias or reticular veins, we suggest transcutaneous laser treatment if the patient has sclerosant allergy, needle phobia, sclerotherapy failure, or small veins (<1 mm) with telangiectatic matting.	2	Weak	Moderate
<b>Varicose tributaries</b>			

Recommendation	Grade <sup>a</sup>	SOR	QOE
For treatment of symptomatic varicose tributaries, we recommend mini phlebectomy or ultrasound-guided sclerotherapy using PCF or PEM.	1	Strong	Moderate
For treatment of symptomatic varicose tributaries, we suggest transilluminated powered phlebectomy as an alternative treatment for patients with clusters of varicosities by a physician who is trained in the procedure.	2	Weak	Low to very low
<b>Treatment of varicose tributaries concomitant or staged with superficial truncal ablation</b>			
For individuals with symptomatic reflux in the GSV or SSV and associated varicosities, we recommend ablation of the refluxing venous trunk and concomitant phlebectomy or ultrasound-guided foam sclerotherapy of the varicosities with PCF or PEM.	1	Strong	Low to very low
For individuals with symptomatic reflux in the AAGSV or PAGSV, we suggest simultaneous ablation of the refluxing venous trunk and phlebectomy or UGFS of the varicosities with PCF or PEM.	2	Weak	Low to very low
For individuals with symptomatic reflux in the GSV or SSV, we suggest ablation of the refluxing venous trunk and staged phlebectomy or UGFS of the varicosities only if anatomical or medical reasons are present. We suggest shared decision-making with the patient regarding the timing of the procedure.	2	Weak	Low to very low
For individuals with symptomatic reflux in the AAGSV or PAGSV, we suggest ablation of the refluxing venous trunk and staged phlebectomy or UGFS of the varicosities only if anatomical or medical reasons are present. We suggest shared decision-making with the patient regarding the timing of the procedure.	2	Weak	Low to very low
<b>Treatment of varicose tributaries concomitant or staged with superficial truncal ablation</b>			
For individuals with varicose veins (CEAP class C2) who have significant, symptomatic axial reflux of the GSV or SSV, we recommend against treatment of incompetent perforating veins concomitant with initial ablation of the saphenous veins.	1	Strong	Low to very low
For individuals with varicose veins (CEAP class C2) who have significant, symptomatic axial reflux of the AAGSV or PAGSV, we suggest against treatment of incompetent perforating veins concomitant with initial ablation of the superficial truncal veins.	2	Weak	Low to very low

AAGSV: anterior accessory great saphenous vein; CEAP: Clinical, Etiologic, Anatomic, Pathophysiologic classification system; EVLA: endovenous laser ablation; GSV: great saphenous vein; HL&S: high ligation and stripping; PCF: physician-compounded foam; PEM: polidocanol endovenous microfoam; PAGSV: posterior accessory great saphenous vein; QOE: quality of evidence; QOL: quality of life; RFA: radiofrequency ablation; SOR: strength of recommendation; SSV: small saphenous vein; UGFS: ultrasound-guided foam sclerotherapy. a Grading: strong=1 or weak=2, based on a level of evidence that is either high quality=A, moderate quality=B, or low quality=C.



## American Vein and Lymphatic Society

In 2015, the American Vein and Lymphatic Society (AVLS, previously named the American College of Phlebology) published guidelines on the treatment of superficial vein disease.<sup>66</sup>

AVLS gave a Grade 1 recommendation based on high quality evidence that compression is an effective method for the management of symptoms, but when individuals have a correctable source of reflux, definitive treatment should be offered unless contraindicated. AVLS recommends against a requirement for compression therapy when a definitive treatment is available. AVLS gave a strong recommendation based on moderate quality evidence that endovenous thermal ablation is the preferred treatment for saphenous and accessory saphenous vein incompetence, and gave a weak recommendation based on moderate quality evidence that mechanochemical ablation may also be used to treat venous reflux.

In 2017, AVLS published guidelines on the treatment of refluxing accessory saphenous veins.<sup>38</sup> The College gave a Grade 1 recommendation based on level C evidence that individuals with symptomatic incompetence of the accessory saphenous veins be treated with endovenous thermal ablation or sclerotherapy to reduce symptomatology. The guidelines noted that although accessory saphenous veins may drain into the great saphenous vein before it drains into the common femoral vein, they can also empty directly into the common femoral vein.

## National Institute for Health and Care Excellence

In 2013, The National Institute for Health and Care Excellence (NICE) updated its guidance on ultrasound-guided foam sclerotherapy for varicose veins. NICE stated that:

“1.1 Current evidence on the efficacy of ultrasound-guided foam sclerotherapy for varicose veins is adequate. The evidence on safety is adequate, and provided that individuals are warned of the small but significant risks of foam embolization (see section 1.2), this procedure may be used with normal arrangements for clinical governance, consent and audit.

1.2 During the consent process, clinicians should inform individuals that there are reports of temporary chest tightness, dry cough, headaches and visual disturbance, and rare but significant complications including myocardial infarction, seizures, transient ischaemic attacks and stroke.”

In 2015, NICE published a technology assessment on the clinical effectiveness and cost-effectiveness of foam sclerotherapy, endovenous laser ablation, and surgery for varicose veins.<sup>65</sup>

In 2016, NICE revised its guidance on endovenous mechanochemical ablation, concluding that "Current evidence on the safety and efficacy of endovenous mechanochemical ablation for varicose veins appears adequate to support the use of this procedure..."

## Medicare National Coverage

There is no national coverage determination.

## Regulatory Status

In 2015, the VenaSeal Closure System (Sapheon, a part of Medtronic) was approved by the US Food and Drug Administration (FDA) through the premarket approval (P140018) process for the permanent closure of clinically significant venous reflux through endovascular embolization with coaptation. The VenaSeal Closure System seals the vein using a cyanoacrylate adhesive agent. FDA product code: PJQ.

In 2013, Varithena (formerly Varisolve), a sclerosant microfoam made with a proprietary gas mix, was approved by the FDA under a new drug application (205-098) for the treatment of incompetent great saphenous veins, accessory saphenous veins and visible varicosities of the great saphenous vein system above and below the knee.

The following devices were cleared for marketing by the FDA through the 501 (k) process for endovenous treatment of superficial vein reflux:

- In 1999, the VNUS Closure system, a radiofrequency device, was cleared by the FDA through the 510(k) process for "endovascular coagulation of blood vessels in individuals with superficial vein reflux." In 2005, the VNUS RFS and RFS*Flex* devices were cleared by the FDA for "use in vessel and tissue coagulation including, treatment of incompetent (i.e., refluxing) perforator and tributary veins." In 2008, the modified VNUS ClosureFAST Intravascular Catheter was cleared by the FDA through the 510(k) process. FDA product code: GEI.
- In 2002, the Diomed 810 nm surgical laser and EVLT (endovenous laser therapy) procedure kit were cleared by the FDA through the 510(k) process, "... for use in the endovascular coagulation of the great saphenous vein of the thigh in individuals with superficial vein reflux." FDA product code: GEX.



- In 2005, a modified Erbe Erbokryo cryosurgical unit (Erbe USA) was approved by the FDA for marketing through the 510(k) process. A variety of clinical indications are listed, including cryostripping of varicose veins of the lower limbs. FDA product code: GEH.
- In 2003, the Trivex system (InaVein), a device for transilluminated powered phlebectomy (TIPP) was cleared by the FDA through the 510(k) process for “ambulatory phlebectomy procedures for the resection and ablation of varicose veins.” FDA product code: DNQ.
- In 2008, the ClariVein Infusion Catheter (Merit Medical) was cleared by the FDA through the 510(k) process (K071468) for mechanochemical ablation. The FDA determined that this device was substantially equivalent to the Trellis Infusion System (K013635) and the Slip-Cath Infusion Catheter (K882796). The system includes an infusion catheter, motor drive, stopcock, and syringe, and is intended for the infusion of physician-specified agents in the peripheral vasculature. FDA product code: KRA.

## References

1. O'Meara S, Cullum NA, Nelson EA. Compression for venous leg ulcers. *Cochrane Database Syst Rev*. Jan 21 2009; (1): CD000265. PMID 19160178
2. O'Meara S, Cullum N, Nelson EA, et al. Compression for venous leg ulcers. *Cochrane Database Syst Rev*. Nov 14 2012; 11(11): CD000265. PMID 23152202
3. Knight Nee Shingler SL, Robertson L, Stewart M. Graduated compression stockings for the initial treatment of varicose veins in people without venous ulceration. *Cochrane Database Syst Rev*. Jul 16 2021; 7(7): CD008819. PMID 34271595
4. Howard DP, Howard A, Kothari A, et al. The role of superficial venous surgery in the management of venous ulcers: a systematic review. *Eur J Vasc Endovasc Surg*. Oct 2008; 36(4): 458-65. PMID 18675558
5. O'Donnell TF. The present status of surgery of the superficial venous system in the management of venous ulcer and the evidence for the role of perforator interruption. *J Vasc Surg*. Oct 2008; 48(4): 1044-52. PMID 18992425
6. Jones L, Braithwaite BD, Selwyn D, et al. Neovascularisation is the principal cause of varicose vein recurrence: results of a randomised trial of stripping the long saphenous vein. *Eur J Vasc Endovasc Surg*. Nov 1996; 12(4): 442-5. PMID 8980434
7. Rutgers PH, Kitslaar PJ. Randomized trial of stripping versus high ligation combined with sclerotherapy in the treatment of the incompetent greater saphenous vein. *Am J Surg*. Oct 1994; 168(4): 311-5. PMID 7943585
8. Farah MH, Nayfeh T, Urtecho M, et al. A systematic review supporting the Society for Vascular Surgery, the American Venous Forum, and the American Vein and Lymphatic Society guidelines on the management of varicose veins. *J Vasc Surg Venous Lymphat Disord*. Sep 2022; 10(5): 1155-1171. PMID 34450355
9. Whing J, Nandhra S, Nesbitt C, et al. Interventions for great saphenous vein incompetence. *Cochrane Database Syst Rev*. Aug 11 2021; 8(8): CD005624. PMID 34378180
10. Paravastu SC, Horne M, Dodd PD. Endovenous ablation therapy (laser or radiofrequency) or foam sclerotherapy versus conventional surgical repair for short saphenous varicose veins. *Cochrane Database Syst Rev*. Nov 29 2016; 11(11): CD010878. PMID 27898181



11. Brittenden J, Cotton SC, Elders A, et al. A randomized trial comparing treatments for varicose veins. *N Engl J Med*. Sep 25 2014; 371(13): 1218-27. PMID 25251616
12. Rass K, Frings N, Glowacki P, et al. Comparable effectiveness of endovenous laser ablation and high ligation with stripping of the great saphenous vein: two-year results of a randomized clinical trial (RELACS study). *Arch Dermatol*. Jan 2012; 148(1): 49-58. PMID 21931012
13. Rass K, Frings N, Glowacki P, et al. Same Site Recurrence is More Frequent After Endovenous Laser Ablation Compared with High Ligation and Stripping of the Great Saphenous Vein: 5 year Results of a Randomized Clinical Trial (RELACS Study). *Eur J Vasc Endovasc Surg*. Nov 2015; 50(5): 648-56. PMID 26319476
14. Christenson JT, Gueddi S, Gemayel G, et al. Prospective randomized trial comparing endovenous laser ablation and surgery for treatment of primary great saphenous varicose veins with a 2-year follow-up. *J Vasc Surg*. Nov 2010; 52(5): 1234-41. PMID 20801608
15. Biemans AA, Kockaert M, Akkersdijk GP, et al. Comparing endovenous laser ablation, foam sclerotherapy, and conventional surgery for great saphenous varicose veins. *J Vasc Surg*. Sep 2013; 58(3): 727-34.e1. PMID 23769603
16. van der Velden SK, Biemans AA, De Maeseneer MG, et al. Five-year results of a randomized clinical trial of conventional surgery, endovenous laser ablation and ultrasound-guided foam sclerotherapy in patients with great saphenous varicose veins. *Br J Surg*. Sep 2015; 102(10): 1184-94. PMID 26132315
17. Wallace T, El-Sheikha J, Nandhra S, et al. Long-term outcomes of endovenous laser ablation and conventional surgery for great saphenous varicose veins. *Br J Surg*. Dec 2018; 105(13): 1759-1767. PMID 30132797
18. Alozai T, Huizing E, Schreve MA, et al. A systematic review and meta-analysis of treatment modalities for anterior accessory saphenous vein insufficiency. *Phlebology*. Apr 2022; 37(3): 165-179. PMID 34965757
19. Hamann SAS, Giang J, De Maeseneer MGR, et al. Editor's Choice - Five Year Results of Great Saphenous Vein Treatment: A Meta-analysis. *Eur J Vasc Endovasc Surg*. Dec 2017; 54(6): 760-770. PMID 29033337
20. Vähäaho S, Mahmoud O, Halmesmäki K, et al. Randomized clinical trial of mechanochemical and endovenous thermal ablation of great saphenous varicose veins. *Br J Surg*. Apr 2019; 106(5): 548-554. PMID 30908611
21. Hamel-Desnos C, Nyamekye I, Chauzat B, et al. FOVELASS: A Randomised Trial of Endovenous Laser Ablation Versus Polidocanol Foam for Small Saphenous Vein Incompetence. *Eur J Vasc Endovasc Surg*. Mar 2023; 65(3): 415-423. PMID 36470312
22. Shadid N, Ceulen R, Nelemans P, et al. Randomized clinical trial of ultrasound-guided foam sclerotherapy versus surgery for the incompetent great saphenous vein. *Br J Surg*. Aug 2012; 99(8): 1062-70. PMID 22627969
23. Lam YL, Lawson JA, Toonder IM, et al. Eight-year follow-up of a randomized clinical trial comparing ultrasound-guided foam sclerotherapy with surgical stripping of the great saphenous vein. *Br J Surg*. May 2018; 105(6): 692-698. PMID 29652081
24. U.S. Food and Drug Administration, Center for Drug Evaluation and Research. Summary Review: 205098 Varithena. 2013; [https://www.accessdata.fda.gov/drugsatfda\\_docs/nda/2013/205098Orig1s000SumR.pdf](https://www.accessdata.fda.gov/drugsatfda_docs/nda/2013/205098Orig1s000SumR.pdf). Accessed June 5, 2024.
25. Todd KL, Wright DI, Gibson K, et al. The VANISH-2 study: a randomized, blinded, multicenter study to evaluate the efficacy and safety of polidocanol endovenous microfoam 0.5% and 1.0% compared with placebo for the treatment of saphenofemoral junction incompetence. *Phlebology*. Oct 2014; 29(9): 608-18. PMID 23864535
26. Vasquez M, Gasparis AP. A multicenter, randomized, placebo-controlled trial of endovenous thermal ablation with or without polidocanol endovenous microfoam treatment in patients with great saphenous vein incompetence and visible varicosities. *Phlebology*. May 2017; 32(4): 272-281. PMID 26957489
27. Deak ST. Retrograde administration of ultrasound-guided endovenous microfoam chemical ablation for the treatment of superficial venous insufficiency. *J Vasc Surg Venous Lymphat Disord*. Jul 2018; 6(4): 477-484. PMID 29909854
28. Bootun R, Lane TR, Dharmarajah B, et al. Intra-procedural pain score in a randomised controlled trial comparing mechanochemical ablation to radiofrequency ablation: The Multicentre Venefit™ versus ClariVein® for varicose veins trial. *Phlebology*. Feb 2016; 31(1): 61-5. PMID 25193822



29. Lane T, Bootun R, Dharmarajah B, et al. A multi-centre randomised controlled trial comparing radiofrequency and mechanical occlusion chemically assisted ablation of varicose veins - Final results of the Venefit versus Clarivein for varicose veins trial. *Phlebology*. Mar 2017; 32(2): 89-98. PMID 27221810
30. Lam YL, Toonder IM, Wittens CH. Clarivein® mechano-chemical ablation an interim analysis of a randomized controlled trial dose-finding study. *Phlebology*. Apr 2016; 31(3): 170-6. PMID 26249150
31. Holewijn S, van Eekeren RRJP, Vahl A, et al. Two-year results of a multicenter randomized controlled trial comparing Mechanochemical endovenous Ablation to RADiOfrequeNcy Ablation in the treatment of primary great saphenous vein incompetence (MARADONA trial). *J Vasc Surg Venous Lymphat Disord*. May 2019; 7(3): 364-374. PMID 31000063
32. Mohamed AH, Leung C, Wallace T, et al. A Randomized Controlled Trial of Endovenous Laser Ablation Versus Mechanochemical Ablation With ClariVein in the Management of Superficial Venous Incompetence (LAMA Trial). *Ann Surg*. Jun 01 2021; 273(6): e188-e195. PMID 31977509
33. Thierens N, Holewijn S, Vissers WH, et al. Five-year outcomes of mechano-chemical ablation of primary great saphenous vein incompetence. *Phlebology*. May 2020; 35(4): 255-261. PMID 31291849
34. U.S. Food and Drug Administration. VenaSeal Closure System. PMA P140018. 2015; <https://www.accessdata.fda.gov/scripts/cdrh/cfdocs/cfpma/pma.cfm?id=P140018>. Accessed June 5, 2024.
35. Morrison N, Gibson K, McEnroe S, et al. Randomized trial comparing cyanoacrylate embolization and radiofrequency ablation for incompetent great saphenous veins (VeClose). *J Vasc Surg*. Apr 2015; 61(4): 985-94. PMID 25650040
36. Gibson K, Ferris B. Cyanoacrylate closure of incompetent great, small and accessory saphenous veins without the use of post-procedure compression: Initial outcomes of a post-market evaluation of the VenaSeal System (the WAVES Study). *Vascular*. Apr 2017; 25(2): 149-156. PMID 27206470
37. Klem TM, Schnater JM, Schütte PR, et al. A randomized trial of cryo stripping versus conventional stripping of the great saphenous vein. *J Vasc Surg*. Feb 2009; 49(2): 403-9. PMID 19028042
38. Gibson K, Khilnani N, Schul M, et al. American College of Phlebology Guidelines - Treatment of refluxing accessory saphenous veins. *Phlebology*. Aug 2017; 32(7): 448-452. PMID 27738242
39. Morrison N, Kolluri R, Vasquez M, et al. Comparison of cyanoacrylate closure and radiofrequency ablation for the treatment of incompetent great saphenous veins: 36-Month outcomes of the VeClose randomized controlled trial. *Phlebology*. Jul 2019; 34(6): 380-390. PMID 30403154
40. Eroglu E, Yasim A. A Randomised Clinical Trial Comparing N-Butyl Cyanoacrylate, Radiofrequency Ablation and Endovenous Laser Ablation for the Treatment of Superficial Venous Incompetence: Two Year Follow up Results. *Eur J Vasc Endovasc Surg*. Oct 2018; 56(4): 553-560. PMID 30042039
41. Alhewy MA, Abdo EM, Ghazala EAE, et al. Outcomes of Cyanoacrylate Closure Versus Radiofrequency Ablation for the Treatment of Incompetent Great Saphenous Veins. *Ann Vasc Surg*. Jan 2024; 98: 309-316. PMID 37802141
42. Morrison N, Gibson K, Vasquez M, et al. VeClose trial 12-month outcomes of cyanoacrylate closure versus radiofrequency ablation for incompetent great saphenous veins. *J Vasc Surg Venous Lymphat Disord*. May 2017; 5(3): 321-330. PMID 28411697
43. Eroglu E, Yasim A, Ari M, et al. Mid-term results in the treatment of varicose veins with N-butyl cyanoacrylate. *Phlebology*. Dec 2017; 32(10): 665-669. PMID 28669248
44. Zierau U. Sealing Veins with the VenaSeal Sapheon Closure System: Results for 795 Treated Truncal Veins after 1000 Days. *Vasomed*. 2015;27:124-127.
45. Disselhoff BC, der Kinderen DJ, Kelder JC, et al. Randomized clinical trial comparing endovenous laser with cryostripping for great saphenous varicose veins. *Br J Surg*. Oct 2008; 95(10): 1232-8. PMID 18763255
46. Disselhoff BC, der Kinderen DJ, Kelder JC, et al. Five-year results of a randomized clinical trial comparing endovenous laser ablation with cryostripping for great saphenous varicose veins. *Br J Surg*. Aug 2011; 98(8): 1107-11. PMID 21633948



47. de Ávila Oliveira R, Riera R, Vasconcelos V, et al. Injection sclerotherapy for varicose veins. *Cochrane Database Syst Rev*. Dec 10 2021; 12(12): CD001732. PMID 34883526
48. Leopardi D, Hoggan BL, Fitridge RA, et al. Systematic review of treatments for varicose veins. *Ann Vasc Surg*. Mar 2009; 23(2): 264-76. PMID 19059756
49. El-Sheikha J, Nandhra S, Carradice D, et al. Clinical outcomes and quality of life 5 years after a randomized trial of concomitant or sequential phlebectomy following endovenous laser ablation for varicose veins. *Br J Surg*. Aug 2014; 101(9): 1093-7. PMID 24916467
50. Yamaki T, Hamahata A, Soejima K, et al. Prospective randomised comparative study of visual foam sclerotherapy alone or in combination with ultrasound-guided foam sclerotherapy for treatment of superficial venous insufficiency: preliminary report. *Eur J Vasc Endovasc Surg*. Mar 2012; 43(3): 343-7. PMID 22230599
51. Michaels JA, Campbell WB, Brazier JE, et al. Randomised clinical trial, observational study and assessment of cost-effectiveness of the treatment of varicose veins (REACTIV trial). *Health Technol Assess*. Apr 2006; 10(13): 1-196, iii-iv. PMID 16707070
52. Luebke T, Brunkwall J. Meta-analysis of transilluminated powered phlebectomy for superficial varicosities. *J Cardiovasc Surg (Torino)*. Dec 2008; 49(6): 757-64. PMID 19043390
53. Chetter IC, Mylankal KJ, Hughes H, et al. Randomized clinical trial comparing multiple stab incision phlebectomy and transilluminated powered phlebectomy for varicose veins. *Br J Surg*. Feb 2006; 93(2): 169-74. PMID 16432820
54. Giannopoulos S, Rodriguez L, Chau M, et al. A systematic review of the outcomes of percutaneous treatment modalities for pathologic saphenous and perforating veins. *J Vasc Surg Venous Lymphat Disord*. Sep 2022; 10(5): 1172-1183.e5. PMID 35364302
55. Ho VT, Adkar SS, Harris EJ. Systematic review and meta-analysis of management of incompetent perforators in patients with chronic venous insufficiency. *J Vasc Surg Venous Lymphat Disord*. Jul 2022; 10(4): 955-964.e5. PMID 35217217
56. Tenbrook JA, Iafrati MD, O'donnell TF, et al. Systematic review of outcomes after surgical management of venous disease incorporating subfascial endoscopic perforator surgery. *J Vasc Surg*. Mar 2004; 39(3): 583-9. PMID 14981453
57. van Gent WB, Catarinella FS, Lam YL, et al. Conservative versus surgical treatment of venous leg ulcers: 10-year follow up of a randomized, multicenter trial. *Phlebology*. Mar 2015; 30(1 Suppl): 35-41. PMID 25729066
58. Blomgren L, Johansson G, Dahlberg-Akerman A, et al. Changes in superficial and perforating vein reflux after varicose vein surgery. *J Vasc Surg*. Aug 2005; 42(2): 315-20. PMID 16102633
59. Lin ZC, Loveland PM, Johnston RV, et al. Subfascial endoscopic perforator surgery (SEPS) for treating venous leg ulcers. *Cochrane Database Syst Rev*. Mar 03 2019; 3(3): CD012164. PMID 30827037
60. Luebke T, Brunkwall J. Meta-analysis of subfascial endoscopic perforator vein surgery (SEPS) for chronic venous insufficiency. *Phlebology*. Feb 2009; 24(1): 8-16. PMID 19155335
61. Lawrence PF, Hager ES, Harlander-Locke MP, et al. Treatment of superficial and perforator reflux and deep venous stenosis improves healing of chronic venous leg ulcers. *J Vasc Surg Venous Lymphat Disord*. Jul 2020; 8(4): 601-609. PMID 32089497
62. Masuda E, Ozsvath K, Vossler J, et al. The 2020 appropriate use criteria for chronic lower extremity venous disease of the American Venous Forum, the Society for Vascular Surgery, the American Vein and Lymphatic Society, and the Society of Interventional Radiology. *J Vasc Surg Venous Lymphat Disord*. Jul 2020; 8(4): 505-525.e4. PMID 32139328
63. Gloviczki P, Comerota AJ, Dalsing MC, et al. The care of patients with varicose veins and associated chronic venous diseases: clinical practice guidelines of the Society for Vascular Surgery and the American Venous Forum. *J Vasc Surg*. May 2011; 53(5 Suppl): 2S-48S. PMID 21536172
64. Gloviczki P, Lawrence PF, Wasan SM, et al. The 2022 Society for Vascular Surgery, American Venous Forum, and American Vein and Lymphatic Society clinical practice guidelines for the management of varicose veins of the lower extremities. Part I. Duplex Scanning and Treatment of Superficial Truncal Reflux: Endorsed by the Society for Vascular Medicine and the International Union of Phlebology. *J Vasc Surg Venous Lymphat Disord*. Mar 2023; 11(2): 231-261.e6. PMID 36326210



65. Gloviczki P, Lawrence PF, Wasan SM, et al. The 2023 Society for Vascular Surgery, American Venous Forum, and American Vein and Lymphatic Society clinical practice guidelines for the management of varicose veins of the lower extremities. Part II: Endorsed by the Society of Interventional Radiology and the Society for Vascular Medicine. J Vasc Surg Venous Lymphat Disord. Jan 2024; 12(1): 101670. PMID 37652254
66. American College of Phlebology. Superficial venous disease. 2015;  
<https://www.myavls.org/assets/pdf/SuperficialVenousDiseaseGuidelinesPMS313-02.03.16.pdf>. Accessed June 5, 2024.
67. Brittenden J, Cotton SC, Elders A, et al. Clinical effectiveness and cost-effectiveness of foam sclerotherapy, endovenous laser ablation and surgery for varicose veins: results from the Comparison of LAser, Surgery and foam Sclerotherapy (CLASS) randomised controlled trial. Health Technol Assess. Apr 2015; 19(27): 1-342. PMID 25858333
68. Giancesini S. Predicting and preventing varicose vein recurrence. Endovascular Today. 2018; 17(3). 45-49. Available at URL: <https://evtoday.com/articles/2018-mar/predicting-and-preventing-varicose-vein-recurrence#:~:text=A%20detailed%20preoperative%20hemodynamic%20evaluation,techniques%20such%20as%20high%20ligation..> Accessed June 5, 2024.
69. Passman Marc. Approach to treating symptomatic superficial venous insufficiency. In UpToDate. Collins, KA (Ed). Waltham, MA. Last updated September 13, 2021. Accessed June 19, 2023.

## History

Date	Comments
12/11/12	Replace policy. Formatting changed to now organize procedures by type of vein. Policy statement extensively revised with additional medically necessary criteria for each procedure. Sclerotherapy now considered medically necessary only for accessory and tributary veins. Policy on hold for provider notification; the effective date is May 19, 2013.
04/08/13	Policy statement clarification. In criteria for sclerotherapy of accessory saphenous veins when not done concurrently with other listed treatments, the moderate to severe saphenous reflux criterion has been removed. To clarify the definition of "symptomatic" for treatment of tributaries not done concurrently with other listed treatments, specific criteria added for stab avulsion, hook phlebectomy, sclerotherapy or transilluminated powered phlebectomy treatment of tributaries. Tributary criterion for moderate to severe saphenous reflux, when not done concurrently with other listed treatments, has been removed.
06/14/13	Minor clarification. Hook phlebectomy clarified to indicate that it is also known as stab phlebectomy or micro-phlebectomy.
10/14/13	Replace policy. CPT codes for sclerotherapy (36468, 36469, 36470, 36471), TIPP (37765 or 37766, stab avulsion (37765, or 37799), etc. added to Policy Guidelines section.
02/27/14	Update Related Policies. Add 10.01.514.
06/09/14	Interim update. Criteria for vein size removed from policy statement. Minor edit to change definition of "moderate to severe reflux" to greater than 0.5 second. Coding



Date	Comments
	update: ICD-9 and ICD-10 diagnosis and procedure codes removed – these are not utilized for adjudication.
02/10/15	Annual Review. Policy updated with literature review through September 23, 2014; reference 8-9, 18, 24 33 added and some references removed; policy statement revised to allow sclerotherapy as medically necessary when criteria are met. Information added regarding FDA approval of Varithena sclerotherapy. Documentation requirements added to Policy Guidelines.
05/12/15	Interim Update. Policy statement clarified: Treatment of tributaries by sclerotherapy, stab avulsion, stab/hook phlebectomy or transilluminated powered phlebectomy may now be considered medically necessary up to 10 days after saphenous veins have been treated. Definition of moderate to severe saphenous reflux and abbreviation “TIPP” added to the policy statement.
06/09/15	Interim Update. Policy statement clarified: TRIVEX listed as an example of TIPP. Exercises and pain relievers removed from conservative management requirement. TRIVEX manufacturer website added to Reference section. CPT codes 76942, 93970-71 and HCPCS code S2202 removed; these are not reviewed.
11/10/15	Interim Update. Policy updated with clarification to coverage criteria for the accessory saphenous vein, indicating parameters around treatment of the greater or lesser saphenous veins and the presence of reflux.
01/12/16	Annual Review. Added statement that cyanoacrylate adhesive/embolization (CAE) (e.g., VenaSeal closure system) and endovenous mechanochemical ablation (MOCA) (e.g. ClariVein) of any vein is considered investigational. The failure of compression therapy removed from the policy statements on venous stasis and thrombophlebitis. References added. Policy updated with literature review through July 7, 2015.
10/01/16	Interim Update, approved September 13, 2016. Perforator vein criteria revised: Requirement of active ulcers changed to “healed or active ulcers” and “demonstrated perforator reflux” is more clearly defined with measurements of outward flow and vein diameter.
12/01/16	Policy moved to new format. Policy statements unchanged. Added Prior Authorization Requirements section.
01/01/17	Coding update, added CPT codes 36473 and 36474 effective 1/1/17.
03/01/17	Annual Review, approved February 14, 2017. No change to policy statement. Compression Therapy added to Definition of Terms. Reference 64 added. Removed CPT code 36469 from policy as it terminated as of 01/01/2015.
11/02/17	Minor formatting edits made.
01/16/18	Minor edit, added Documentation Requirements table to the Policy Coverage Criteria section.
01/23/18	Coding update, added CPT codes 36465, 36466, 36482, and 36483 (new codes effective 1/1/18).





Date	Comments
08/01/18	Annual Review, approved July 25, 2018. Policy updated with literature review through March 2018; references 18, 21, 24-27, and 30-31 added; references 54 and 56 updated. Policy statements unchanged.
11/01/18	Interim Review, approved October 9, 2018. Reordered and clarified policy statement criteria by procedure type rather than vein type. Added criteria for number of treatment sessions of sclerotherapy allowed and criteria for requests for sclerotherapy after ablation of the saphenous veins for the treatment of residual or recurrent symptoms.
01/01/19	Interim Review, approved December 19, 2018. Added missing wording to statement: "Phlebectomy (stab avulsion, hook phlebectomy, or TIPP) or initial* sclerotherapy as a component of the treatment of <u>symptomatic varicose tributaries</u> when performed <b>either</b> at the same time <b>or following prior treatment</b> (surgical, radiofrequency, or laser) of the saphenous veins is considered medically necessary" to clarify the intent of the statement. Added new HCPCS code 0524T (new code effective 1/1/19).
04/01/19	Annual Review, approved March 19, 2019. Policy updated with literature review through November 2018; references 16, 19, 33-34 added. Minor edits to policy statements for clarity; otherwise intent of policy statements unchanged.
08/01/19	Interim Review, approved July 11, 2019. Policy updated with literature review through March 2019, references 60, and 65-67 added. Cyanoacrylate adhesive may be considered medically necessary. A statement was added on concurrent treatment of the accessory saphenous veins.
12/01/19	Interim Review, approved November 26, 2019. Policy effective date changed to January 1, 2020.
04/01/20	Delete policy, approved March 10, 2020. This policy will be deleted effective July 2, 2020, replaced with policy 10.01.530.
07/02/20	Delete policy.
11/01/20	Policy reinstated effective February 5, 2021 approved October 13, 2020. Policy updated with literature review through March 2020; references added. Policy statements unchanged
09/01/21	Annual Review, approved August 10, 2021. Policy updated with literature review through April 6, 2021; references added. Removed ligation and stripping, phlebectomy, ultrasound guidance, and SEPS of incompetent perforator veins policy statements, and documentation requirement of CEAP 2 or greater. Removed CPT codes: 37500, 37700 ,37718, 37722, 37735, 37760, 37761, 37765, 37766, 37780, and 37785.
12/01/21	Removed investigational policy statement for Sclerotherapy techniques, other than microfoam sclerotherapy (e.g., Varithena/polidocanol), of great, small, or accessory saphenous veins.



Date	Comments
08/01/22	Annual Review, approved July 11, 2022. Policy updated with literature review through March 23, 2022; references added. Policy statements unchanged.
03/01/23	Interim Review, approved February 20, 2023. Clarified that all endovenous ablation procedures of tributary veins is considered investigational. Changed the wording from "patient" to "individual" throughout the policy for standardization.
08/01/23	Annual Review, approved July 11, 2023. Policy updated with literature review through April 4, 2023; references added. Added clarifying policy statements: Endovenous radiofrequency or laser ablation of tributary veins is considered investigational, and sclerotherapy techniques, other than microfoam sclerotherapy, of great, small, or accessory saphenous veins are considered investigational. Other minor editorial refinements to policy statements; intent unchanged.
06/01/24	Interim Review, approved May 14, 2024. Added policy statement that endovenous chemical ablation with (microfoam sclerotherapy, i.e., Varithena [polidocanol 1%]) of tributary veins is considered investigational.
08/01/24	Annual Review, approved July 8, 2024. Policy updated with literature review through April 5, 2024; references added. Policy statements unchanged.
11/01/24	Interim Review, approved October 21, 2024. Changed policy statement from "Sclerotherapy techniques, other than microfoam sclerotherapy (i.e., Varithena [polidocanol 1%]) of great, small, or accessory saphenous veins are considered investigational" to "Sclerotherapy techniques, (e.g., Sotradecol [sodium tetradecyl sulfate], Asclera [polidocanol injection], physician-compounded foam) of great, small, or accessory saphenous veins are considered investigational. (36470, 36471)" for greater clarity, otherwise policy statements unchanged.

**Disclaimer:** This medical policy is a guide in evaluating the medical necessity of a particular service or treatment. The Company adopts policies after careful review of published peer-reviewed scientific literature, national guidelines and local standards of practice. Since medical technology is constantly changing, the Company reserves the right to review and update policies as appropriate. Member contracts differ in their benefits. Always consult the member benefit booklet or contact a member service representative to determine coverage for a specific medical service or supply. CPT codes, descriptions and materials are copyrighted by the American Medical Association (AMA). ©2024 Premera All Rights Reserved.

**Scope:** Medical policies are systematically developed guidelines that serve as a resource for Company staff when determining coverage for specific medical procedures, drugs or devices. Coverage for medical services is subject to the limits and conditions of the member benefit plan. Members and their providers should consult the member benefit booklet or contact a customer service representative to determine whether there are any benefit limitations applicable to this service or supply. This medical policy does not apply to Medicare Advantage.

